Magnetic Resonance Arthrography of the Wrist and Elbow

Gary M. LiMarzi, MD[a,b], M. Cody O'Dell, MD[a,b], Kurt Scherer, MD[a,b], Christopher Pettis, MD[a,b], Christopher W. Wasyliw, MD[a,b], Laura W. Bancroft, MD[a,b,*]

KEYWORDS

• MR arthrography • Scapholunate ligament tear • Ulnar collateral ligament tear • Olecranon stress fracture • Osteochondritis dissecans

KEY POINTS

- Magnetic resonance (MR) arthrography is highly sensitive and specific for the diagnosis of scapholunate ligament tears.
- MR dictations should state if tears are partial-thickness or full-thickness, and if the tearing involves the dorsal, membranous, and/or volar components of the ligament.
- Partial-thickness tears of the anterior band of the ulnar collateral ligament in overhead-throwing athletes are well evaluated with MR arthrography.
- Repetitive valgus elbow stress and rapid elbow extension during the late stages of throwing may result in an olecranon stress fracture, with propagation from a structural weak point in the trochlear groove.
- Osteochondritis dissecans of the elbow is an osteochondral injury classically seen in adolescent or young adult athletes, especially baseball pitchers, due to repetitive valgus impaction injury of the radial head and developing ossification center of the capitellum.

MAGNETIC RESONANCE ARTHROGRAPHY OF THE WRIST

Wrist pain is a common, nonspecific patient complaint that may be secondary to a variety of underlying processes, both degenerative and traumatic. Wrist trauma can be divided into 2 categories: low impact and high impact. High-impact trauma can lead to displaced fractures, dislocations, and acute tears of the ligaments and tendons, whereas low-impact trauma can lead to more occult injuries.[1] Both mechanisms can result in injuries to the intrinsic and extrinsic carpal ligaments, as well as the triangular fibrocartilage complex (TFCC). Because the TFC is discussed in depth in the article by Cody et al, elsewhere in this issue, this article will not focus on its normal imaging appearance or pathology. Because clinical presentations can overlap significantly, magnetic resonance (MR) arthrography is essential in the diagnostic workup of such injuries. MR arthrography of the wrist is generally preferred over conventional MR imaging or computed tomography (CT) arthrography because of its high intrinsic contrast

The authors have nothing to disclose.

[a] Florida Hospital Diagnostic Radiology Residency Program, Department of Radiology, Florida Hospital, University of Central Florida College of Medicine, 601 East Rollins, Orlando, FL 32803, USA; [b] Department of Radiology, Florida Hospital, University of Central Florida College of Medicine, 6850 Lake Nona Boulevard, Orlando, FL 32827, USA

* Corresponding author.

E-mail address: Laura.bancroft.md@flhosp.org

Magn Reson Imaging Clin N Am 23 (2015) 441–455

http://dx.doi.org/10.1016/j.mric.2015.04.003

1064-9689/15/$ – see front matter

resolution, as well as the ability to evaluate extra-articular soft tissue pathology. MR arthrography is indicated to evaluate TFCC, intrinsic and extrinsic carpal ligaments, and the distal radial ulnar joint (DRUJ).[2]

Technique

The use of intra-articular contrast agents provides an effective means of evaluating the TFCC and interosseous ligaments of the wrist. There is variability among institutions as to whether to perform single-compartment (most commonly radiocarpal), 2-compartment, or rarely 3-compartment (radiocarpal, DRUJ, and midcarpal) arthrography before MR arthrography. Injections are most commonly performed under fluoroscopic guidance, but some radiologists prefer sonographic guidance.[3] Radiocarpal injections are approached most commonly from a dorsal approach; however, some radiologists choose a lateral approach.[4] With the patient supine on the fluoroscopy table, the patient's wrist is placed in a flexed position and bolstered with a rolled towel. The radiocarpal joint is visualized in profile and the skin overlying the joint is marked at the level of the mid scaphoid. After prepping and draping the dorsum of the wrist, local anesthesia is administered with a 25-gauge, 1.5-inch anesthesia needle from a dorsal approach, and the needle is advanced into the radiocarpal joint. Connector tubing flushed with injectate from the syringe is connected to the needle after dripping contrast into the needle hub to displace any air. Although some radiologists inject only a small amount of iodinated contrast to confirm needle placement before injecting the dilute gadolinium mixture, it is also acceptable to combine the iodinate contrast and gadolinium together. While taking rapid cine images, an approximately 3-mL mixture of iodinated contrast and dilute gadolinium is injected into the radiocarpal joint, or until resistance is perceived (**Fig. 1**). The gadolinium-based contrast used in MR arthrography is usually diluted in normal saline and/or iodinated contrast to a concentration of 1:250, which optimizes the paramagnetic effects of gadolinium at 1.5-T field strengths. After removal of the needle, the wrist is then briefly exercised and conventional arthrographic images are obtained in the anteroposterior, lateral, and oblique images before MR arthrography. Some radiologists also prefer taking dedicated spot imaging of the scapholunate (SL) ligament with ulnar deviation or clenched fist stress maneuver. This arthrographic imaging is diagnostic, and is instrumental in cases of patients unable to complete the MR portion of the examination for a variety of reasons.

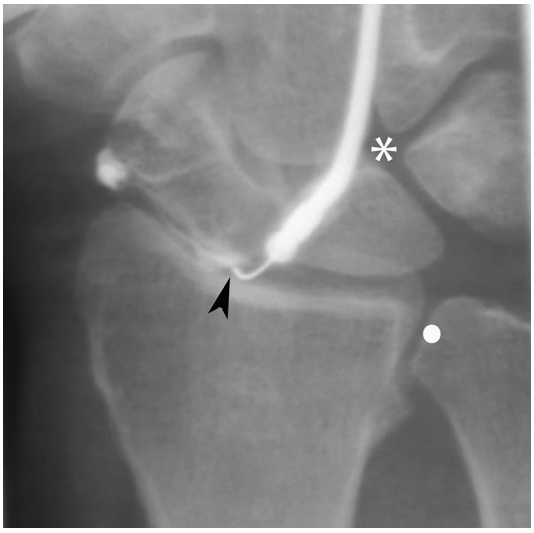

Fig. 1. Wrist arthrogram in a 70-year-old man before MR arthrography. Anteroposterior view of the wrist at the beginning of arthrogram demonstrates radiocarpal injection of 1:250 ratio of gadolinium to iodinated contrast through a 25-gauge needle (*arrowhead*) before MR arthrogram. Asterisk indicates site for midcarpal injection, and circle indicates site for distal radioulnar injection.

Midcarpal joint injections are most commonly performed from a dorsal approach into to the central portion of the 4-part junction of the lunate, triquetrum, hamate, and capitate. Distal radioulnar joint injection is performed from a dorsal approach, with the needle extending to the radial aspect of the ulnar head.

Contraindications

Besides the normal contraindications for MR imaging, the only absolute contraindication for arthrography is local infection of the skin or subcutaneous tissue.[5] One would not want to contaminate a joint by crossing a needle through infected tissues. Usually, patients who cannot undergo MR arthrography are able to tolerate imaging with CT arthrography. For example, patients with implantable cardiac pacemakers who, with some recent exceptions due to new MR imaging-safe pacemakers, cannot undergo MR arthrography, can be safely evaluated with CT.[5–8] A history of adverse contrast reactions with either iodinated or gadolinium-based agents is considered a relative contraindication and should be evaluated on a case-by-case basis.[5]

Complications

Arthrography is a generally well-tolerated procedure with few significant risks, and complications

following arthrography are uncommon and usually in the form of pain. This can be due to overdistention of the joint space, irritation of surrounding nerves, or from intravasation of injected contrast into adjacent muscles.[5,7,8] Synovitis caused by the contrast also may be irritating and painful. Infection is an inherent risk to all percutaneous procedures, but is very rare.

Magnetic Resonance Acquisition

Wrist MR arthrography should be obtained on a 1.5-T or preferably a 3.0-T magnet in a dedicated wrist coil for optimal image quality, and thin-section imaging and small field of view should be used (**Table 1**).[9–13] Patients are optimally scanned in the prone position with the arm extended overhead and the wrist in neutral positioning near the isocenter of the magnet ("Superman" position).[13] If patients cannot tolerate this positioning, imaging is done with the wrist by the patient's side, with care to optimize fat suppression. MR arthrography includes axial, coronal, and sagittal imaging planes, and the coronal and sagittal sequences are prescribed relative to a plane intersecting the hook of the hamate and the palmar margin of the trapezium (**Fig. 2**). Most sequences are obtained with turbo spin echo (TSE) T1-weighting with fat suppression, to take advantage of the T1 properties of the injected gadolinium; T1-weighted images without fat suppression and T2-weighted images with fat suppression also are obtained. T2-weighted fat-suppressed and non–fat-suppressed T1-weighted images are useful in evaluating the marrow. T2-weighted images can detect noncommunicating tears of the intrinsic ligaments and TFCC on the opposite side of the injected joint, marrow edema, and noncommunicating periarticular fluid collections. Some centers also prefer using gradient-echo sequences or 3-dimensional volumetric sequences. Although uncommonly used, some investigators use finger trap distraction with weights suspended from the fingers to accentuate the amount of contrast in the SL interval, widening of the space, and disruption of Gilula carpal arcs.[14,15]

Table 1
Sample wrist MR arthrogram protocol, using 1.5-T or 3.0-T magnet and dedicated wrist coil after radiocarpal injection of dilute gadolinium mixture

Plane	Sequence	FOV, cm	Slice Thickness, mm
Axial	TSE T1 FS	15	3
Coronal	TSE T1 FS	15	2
Sagittal	TSE T1 FS	15	3
Coronal	TSE T2 FS	15	2
Coronal	TSE T1	15	2

Abbreviations: FOV, field of view; FS, fat saturation; TSE, turbo spin echo.

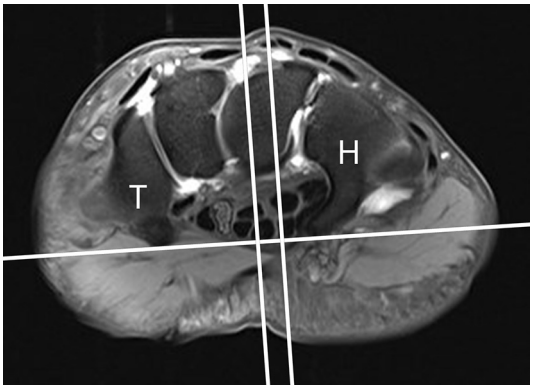

Fig. 2. Axial scout for prescription of coronal and sagittal views. A plane intersecting the hook of the hamate (H) and the palmar margin of the trapezium (T) serves as the reference plane for coronal acquisitions (*single line*). Sagittal images are prescribed from the axis perpendicular (*double lines*) to the coronal plane.

NORMAL ANATOMY

Intrinsic Ligaments

The intrinsic and extrinsic interosseous ligaments of the wrist provide stability to the carpus. The SL ligament is the most commonly injured intrinsic carpal ligament and can predispose to carpal instability.[1,16–20] Patients with ligamentous injury typically present with dorsal wrist pain, crepitus with motion, weakness, and swelling. The SL ligament consists of the bandlike dorsal and volar components connected by the membranous portion composed of a proximal fibrocartilaginous membrane; the dorsal component is considered the primary SL stabilizer (**Fig. 3**).[16–20] The lunotriquetral (LT) ligament is similar in composition to the SL ligament; however, the volar rather than the dorsal component is considered the primary stabilizer of the LT ligament.[16–21] These ligaments provide a barrier between the radiocarpal and midcarpal spaces.[20] CT and MR arthrography have been shown to be more sensitive than standard MR for detecting abnormalities of these ligaments, and MR is superior to CT in detecting other causes of patient's symptoms, such as osteonecrosis, tendon and tendon sheath pathology, synovitis, fluid collections, and masses.[20]

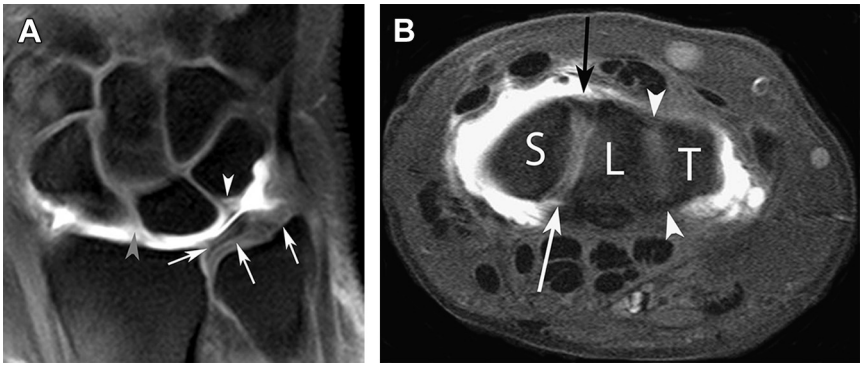

Fig. 3. Normal wrist MR arthrogram. (*A*) Coronal TSE fat-suppressed image after radiocarpal joint injection of dilute gadolinium mixture demonstrates normal appearance of the SL ligament (*gray arrowhead*), LT ligament (*white arrowhead*), and the TFC (*arrows*). (*B*) Axial image through the SL (*arrows*) and LT (*arrowheads*) ligaments show the thicker bandlike portions of the dorsal ligaments compared with the volar components. L, lunate; S, scaphoid; T, triquetrum.

Extrinsic Ligaments

The extrinsic ligaments of the wrist are shown to better advantage with MR arthrography due to joint distention. Dorsally, the extrinsic ligaments are the dorsal radiocarpal ligament (DRCL) and the dorsal intercarpal ligament (DICL) (**Fig. 4**).[13,22,23] These ligaments generally demonstrate homogeneously low signal intensity on MR imaging.[13,22,23] Volar extrinsic ligaments include the radioscaphocapitate ligament (RSCL), radiolunotriquetral ligament (RLTL, also known as the long radiolunate ligament), and the short radiolunate ligament. The RSCL is the most important volar extrinsic ligament, and the RSCL and RLTL can contain normal bands of higher signal on MR imaging/MR arthrography.[13,22,23] The radial collateral ligament (RCL) of the wrist arises as a focal condensation of the joint capsule, just deep to the extensor tendon sheath; it originates from the radial styloid and inserts onto the scaphoid waist.[13,22] Carpal instability may occur when there is concomitant injury to the intrinsic and extrinsic interosseous ligaments.[1,22]

PATHOLOGY

Scapholunate Ligament

MR arthrography's ability to localize the precise location of the tear can help distinguish stable from potentially unstable injuries. Tears of the membranous portion of the SL ligament are usually degenerative and are not associated with carpal instability.[17] Complete SL ligament tears are identified on conventional and MR arthrography by contrast extending from the radiocarpal to the midcarpal joint space through a SL interval defect. In advanced cases, widening of the SL interval also can be seen.[17] Partial tears result in variable

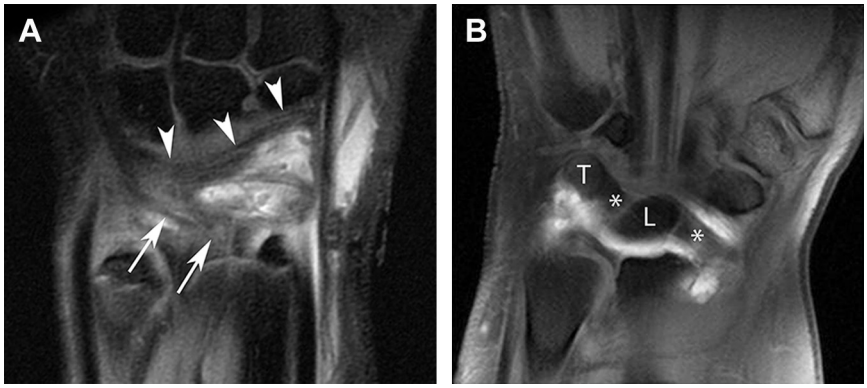

Fig. 4. Extrinsic ligaments. (*A*) Coronal image through the dorsal joint capsule of the wrist shows the normal dorsal radiocarpal (*arrows*) and dorsal intercarpal (*arrowheads*) ligaments. These intact ligaments are shown to better advantage with MR arthrography due to joint distention. (*B*) Coronal MR arthrogram through the volar wrist shows the volar radiolunotriquetral (RLT) ligament (*asterisks*). L, lunate; T, triquetrum.

intravasation of contrast through the torn fibers and outline the abnormal morphology of the tear. SL ligament injuries typically occur in the setting of axial overload or hyperextension with supination, often in the setting of a fall.[1] There also is increased association of SL ligament tears with intra-articular fractures. When isolated, SL ligament tears usually do not cause carpal malalignment (Figs. 5 and 6). Disruption of the secondary stabilizers of the scaphoid leads to rotation of the scaphoid with proximal subluxation, as well as dorsal extension of the lunate, resulting in dorsal intercalated segmental instability (DISI).[1,16,17,24]

Magnetic Resonance Arthrography Accuracy: Scapholunate Ligament

Although conventional MR imaging can detect partial and complete tears of the intrinsic carpal ligaments by the presence of focal thinning or discontinuity, MR arthrography is widely preferred due to improved sensitivity.[17] Arthrographic sensitivity for SL ligament tears has been shown to range widely. Scheck and colleagues[12] demonstrated 90% sensitivity/87% specificity with MR arthrography, compared with 52% sensitivity/34% specificity on conventional MR imaging. Lee and colleagues[8] also demonstrated superior accuracy of MR arthrography (85.0% sensitivity/96.4% specificity) when compared with conventional MR imaging (65% sensitivity/100% specificity) in the evaluation of SL ligament tears. Compared with arthroscopy, Magee and colleagues[25] reported that MR arthrography with 3 T yielded 100% sensitivity and specificity for the detection of SL ligament tears.

Dorsal Intercalated Segmental Instability

The 4 main categories of carpal instability include dissociative carpal instability, nondissociative carpal instability, complex carpal instability, and adaptive carpal instability.[16,24] Although carpal instability may be suggested radiographically in cases of static instability, patients will invariably undergo MR imaging for evaluation of dynamic instability and treatment planning. DISI is one of the dissociative instabilities that occurs when there is disruption of the SL.[17] As on radiographs, MR will also show dorsal tilt of the lunate with a capito-lunate angle greater than 30°, hyperflexion of the scaphoid, and incongruity of Gilula arcs in the presence of DISI deformity (Fig. 7). MR arthrography may be helpful to also assess tears or excessive stretching of the secondary stabilizers of the scaphoid, such as the volar distal scaphotrapezial, dorsal intercarpal and SL ligaments.[17]

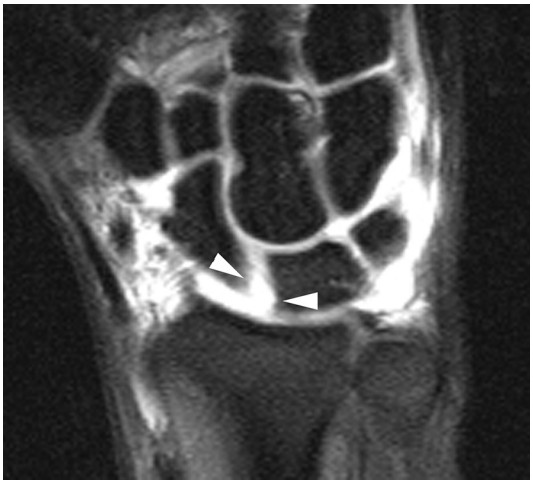

Fig. 6. Complete SL ligament rupture. Coronal MR arthrogram shows contrast filling the widened SL interval (*arrowheads*) due to complete rupture of the SL ligament and SL dissociation.

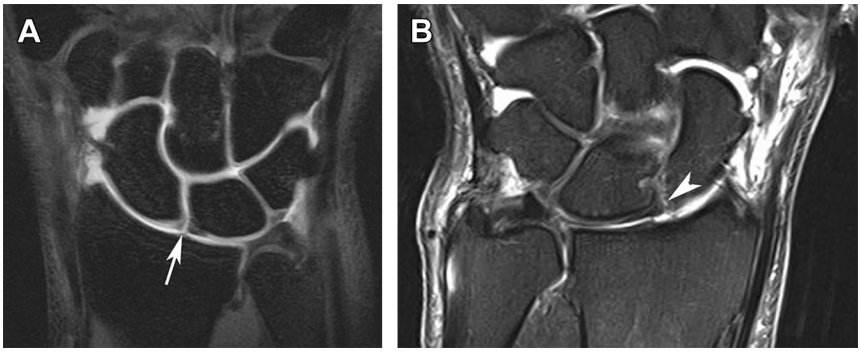

Fig. 5. SL ligament tears. (*A*) Coronal MR arthrogram in a 29-year-old man with wrist pain demonstrate full-thickness tear of the SL ligament (*arrow*), with opacification of the midcarpal joint space due to the communication from the tear. (*B*) Coronal TSE T2-weighted image from MR arthrogram in 70-year-old man with wrist pain shows irregular tearing of the volar aspect of the SL ligament (*arrowhead*).

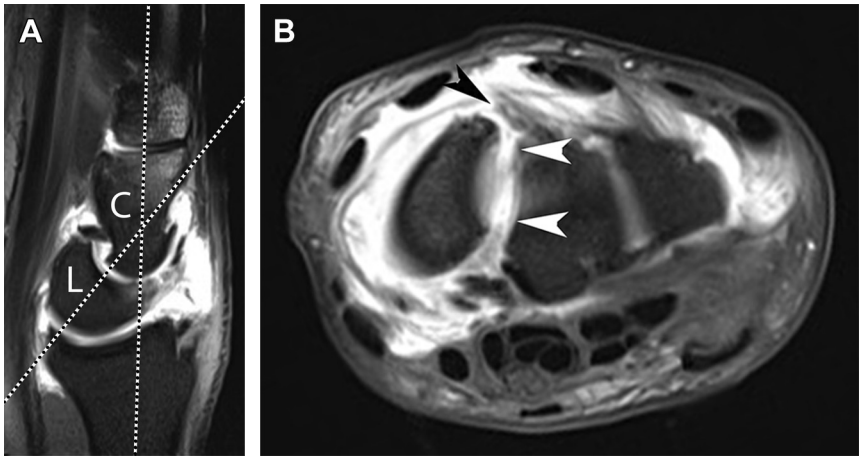

Fig. 7. Dorsal intercalated instability in 43-year-old man with traumatic SL and extrinsic dorsal ligament tears. (*A*) Sagittal MR arthrogram shows dorsal tilt of the lunate 'L' relative to the capitates 'C,' with increased lunate-capitate angle greater than 30°. (*B*) Axial MR arthrogram also shows rupture of the DRCL (*black arrowhead*) and full-thickness tears of the dorsal and membranous portions of the SL ligament (*white arrowheads*), accounting for contrast extension into the midcarpal joint.

Lunatotriquetral Ligament

Injuries to the LT ligament are much less common than those involving the SL ligament; LT ligament tears may be misdiagnosed clinically as TFCC pathology in patients presenting with ulnar-sided wrist pain.[1,17] As with SL ligament injury, isolated LT ligament tears are generally stable. Disruption of the secondary triquetral stabilizer, the radiolunotriquetral ligament, predisposes to volar intercalated segmental instability, in which there is palmar rotation of the lunate and scaphoid.[16,17,24]

Magnetic Resonance Arthrography Accuracy: Lunatotriquetral Ligament

Conventional MR imaging is unreliable in excluding pathology of the LT ligament due to inconsistent visualization in healthy patients. MR arthrography has been shown to have sensitivity for LT ligament tears of up to 56%, when considering both complete and partial tears (**Fig. 8**).[17] A series of 35 patients demonstrated a sensitivity and specificity of 100% for complete tears of the SL and LT ligaments with 3-T MR arthrography.[13] LT ligament tearing may be accompanied by tearing of the TFCC and lunate chondromalacia in the setting of ulnolunate impaction (see **Fig. 8**). Compared with arthroscopy, Magee and colleagues[25] reported that MR arthrography yielded 100% sensitivity and specificity for the detection of LT ligament tears.

Ulnocarpal Impaction Syndrome

Ulnocarpal impaction syndrome is caused by repetitive impaction injury between the ulnar head, TFCC, and carpus, resulting in a spectrum of pathology. Ulnocarpal impaction is usually seen in the setting of positive ulnar variance, either congenital or posttraumatic, with distal radial malunion.[16,17,24] The TFC is thinner in patients with

Fig. 8. LT ligament tear and ulnolunate impaction in 49-year-old man with chronic wrist pain. Coronal MR arthrogram shows a linear tear of the LT ligament (*arrowhead*) with extension of contrast into the midcarpal joint and Palmer 2E TFCC defect (*arrows*) with injected contrast and synovitis in the DRUJ. The subchondral cyst and enhancing marrow in the proximal, medial lunate, chondromalacia involving the abutting surfaces of the ulnar and lunate, and mild ulnar positive variance are classic findings of ulnolunate impaction.

positive ulnar variance and loading of the ulnar carpus is increased, both factors that may predispose to increased rates of TFCC pathology.[11,17,21] Increasing the ulnar variance by 2.5 mm will increase the ulnar load by 42%, more than twice the normal amount.[9] In rare cases, similar degenerative findings may be seen in the setting of a hypertrophic ulnar styloid with negative ulnar variance, referred to as ulnar styloid impaction syndrome (see **Fig. 8**).

MAGNETIC RESONANCE ARTHROGRAPHY OF THE ELBOW

In North America, MR arthrographic evaluation of the elbow is most commonly performed to investigate pain in throwing athletes and patients sustaining trauma from severe valgus stresses, posterorlateral rotator subluxation, and dislocation.[5] Typically, the pain is medial and occurs during the late-cocking phase of throwing, at the point of maximal valgus stress on the medial elbow stabilizers. Unsurprisingly, baseball pitchers, both amateur and professional, comprise a significant portion of patients undergoing arthrography in this part of the world.[5,26] Elsewhere, elbow arthrography is generally used to evaluate acute traumatic injury, namely posterolateral rotatory subluxation and severe valgus injuries.[5] Although less commonly performed than arthrography of the shoulder and knee, elbow arthrography is an important means of investigating intra-articular and ligamentous pathology. Direct arthroscopy is rarely performed as a first-line examination because of the excellent ability of MR and CT arthrography to demonstrate relevant pathology that can then guide arthroscopic evaluation or surgical intervention. Distention of the joint capsule with intra-articular contrast greatly improves visualization of articular and ligamentous structures, which would be overlooked on conventional imaging, increasing the sensitivity of the examination.[5] Contrast in the joint space helps separate closely related structures and provides improved image contrast. Detection of subtle pathology, including partial ligament tears and early osteochondral injury, also is improved.

MR arthrography is typically considered superior to CT arthrography because of improved soft tissue contrast resolution and the ability to obtain source images in multiple planes; however, CT possesses better spatial resolution and is the preferred modality for select patients.[26] Individuals with pacemakers, non-MR safe implantable devices, or who cannot tolerate gadolinium-based contrast agents are excellent candidates for CT arthrography.[5,26] Both modalities are considered far superior to conventional arthrography, which has been largely replaced in modern practice. The most common clinical indications for MR arthrography include detecting injuries to the capsule and supporting ligaments, the presence of intra-articular bodies, and focal osteochondral injury.[5,26]

Technique

The lateral approach into the radiocapitellar joint is the most commonly used approach for accessing the elbow joint. After palpating the radiocapitellar joint with patient pronating and supinating the forearm, the overlying skin is marked. The patient should preferably be positioned prone (in case of vasovagal reaction) or seated with the elbow flexed at 90° and in supination so that the thumb points toward the ceiling.[5] The radiocapitellar joint is visualized and marked under fluoroscopy. Using the general arthrographic principles described previously, local anesthetic is administered from a direct lateral approach with 25-gauge needle, and then the needle is advanced into the radiocapitellar joint. Intra-articular needle placement is confirmed when contrast can be seen flowing freely away from the needle (**Fig. 9**). The solution of diluted gadolinium is then injected for a total volume of 6 to 10 mL or until resistance is felt.

Occasionally, practitioners may elect to abandon the lateral approach in favor of a posteromedial approach.[27] This is usually done when there is clinical concern regarding the lateral ligament complex, because the lateral approach may lead to a small amount of contrast leaking through the percutaneous access site, which can lead to a false-positive diagnosis of lateral ligamentous pathology.[5,28] The patient is positioned supine with the shoulder abducted over the head and the elbow in pronation and approximately 30° of flexion. The medial epicondyle is identified and the skin entry site is marked approximately 1 cm lateral to the epicondyle on the posterior aspect of the arm, reducing the risk of injury to the ulnar nerve.[5] Once the patient is prepped and draped, the needle is directed anterolaterally toward the olecranon fossa. At this point, the examination proceeds in an identical fashion to that of a lateral approach.

Magnetic Resonance Acquisition

During the actual MR image acquisition, the patient may be positioned either prone with the elbow extended overhead, the "Superman" position, or supine with the elbow extended along the body (**Table 2**).[29] Images are obtained in axial, coronal, and sagittal planes. A plane intersecting the

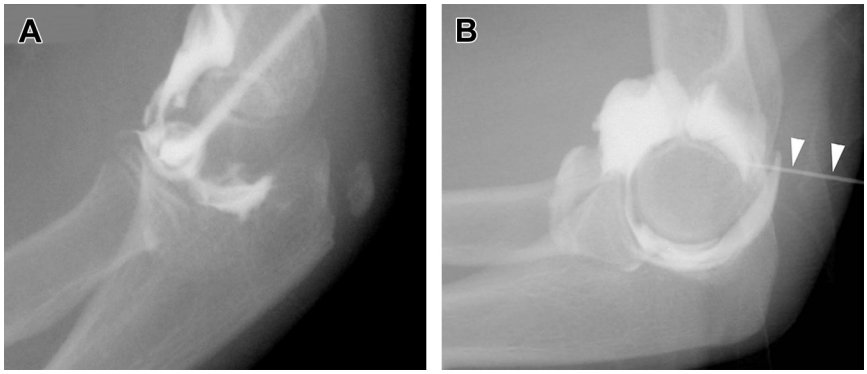

Fig. 9. Fluoroscopically guided elbow arthrography from standard lateral (*A*) and posterior (*B*) approaches in a 9-year-old boy and an 11-year-old girl, respectively. (*A*) After palpating the radiocapitellar joint, with the patient pronating and supinating the forearm, the overlying skin is marked for direct lateral approach into the radiocapitellar joint with 25-gauge needle. (*B*) The posterior approach (*arrowheads*) is an alternate route that will avoid misinterpretation of extravasated contrast about the lateral collateral ligament as pathology.

medial and lateral humeral epicondyles serves as the reference plane for coronal acquisitions, and sagittal images are prescribed from the axis perpendicular to the coronal plane (**Fig. 10**). MR arthrography uses T1-weighted sequences, which provide a higher signal-to-noise ratio than T2-weighted sequences and also require less time, therefore causing less motion artifact.[5,30] Fat-suppressed T1-weighted sequences are performed in the axial, coronal, and sagittal planes. Fat-suppressed T2-weighted images also are obtained, usually in the axial and coronal planes. By combining contrast-enhanced and fluid-sensitive sequences, the elbow can be evaluated for stress fractures/contusions and extra-articular pathology, such as nerve and muscle pathology, and tendon injuries (particularly enthesopathic changes of the common extensor and flexor tendon origins).[5] Some institutions also prefer using gradient-echo sequences or 3-dimensional volumetric sequences.

Table 2
Sample elbow MR arthrogram protocol using 1.5-T or 3.0-T magnet and dedicated elbow coil after injection of dilute gadolinium mixture

Plane	Sequence	FOV, cm	Slice Thickness, mm
Coronal	TSE T1 FS	15	2.5
Sagittal	TSE T1 FS	15	2.5
Axial	TSE T1 FS	15	2.5
Coronal	TSE T2 FS	15	2.5
Coronal	TSE T1	15	2.5

Abbreviations: FOV, field of view; FS, fat saturation; TSE, turbo spin echo.

Normal Anatomy

The elbow is a synovial-lined, encapsulated joint composed of 3 distinct articulations: the radiocapitellar, ulnohumeral, and proximal radioulnar joints.[30] Of these, the biggest contributor to elbow stability is the ulnohumeral joint, responsible for 55% to 75% of joint restriction in extension and flexion, respectively.[29] The radiocapitellar joint, although playing a lessor role in joint stability, is responsible for transmitting 60% of the axial load from the forearm.[29] There is a normal, mild degree of lateral angulation of the humerus and ulna, referred to as the valgus carrying angle of the

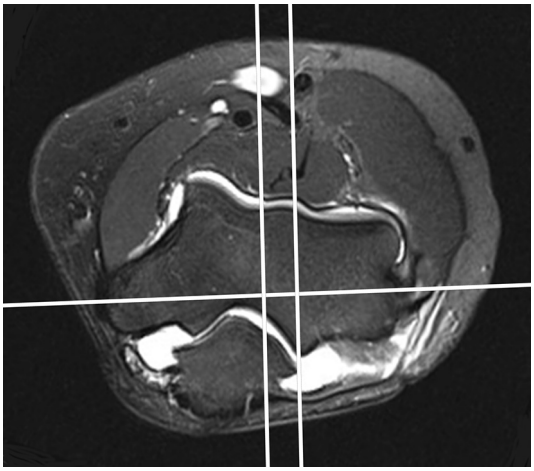

Fig. 10. Axial scout for prescription of coronal and sagittal views. A plane intersecting the medial and lateral humeral epicondyles serves as the reference plane for coronal acquisitions (*single line*). Sagittal images are prescribed from the axis perpendicular (*double lines*) to the coronal plane.

elbow. This is usually between 10 and 20° and predisposes the elbow to valgus instability, whereas varus instability remains uncommon.[29]

Ligamentous supporting structures of the elbow arise as focal condensations of the joint capsule and are divided into medial and lateral complexes.[29,30] These provide stability under valgus and varus stresses, respectively. The medial complex consists of the anterior and posterior bundles of the ulnar collateral ligament (UCL, also known as the medial collateral ligament) as well as the transverse ligament (**Fig. 11**A). The lateral complex includes the RCL, the lateral UCL (LUCL), and the annular ligament (see **Fig. 11**B). The most important component of the medial ligament complex is the anterior bundle of the UCL, which provides the most resistance against valgus forces.[29,31] Both bundles of the UCL originate from the inferior aspect of the medial epicondyle; the anterior bundle inserts on the sublime tubercle of the ulna and the posterior bundle forms the floor of the cubital tunnel.[26,29] The posterior bundle inserts on the trochlear notch and helps resist internal rotation. The transverse ligament spans between the anterior and posterior bundles of the UCL and is poorly visualized with MR.[29] Superficially, the UCL is in close relationship to the flexor muscle group. On MR imaging, the UCL has a striated appearance in more than 90% of healthy volunteers, which should not be confused with injury.

The annular ligament serves an important role as a stabilizer of the proximal radioulnar joint and is more clinically relevant in pediatric patients than adults.[29] It inserts twice on the lesser sigmoid notch of the ulna after enveloping the radial head. The LUCL provides most of the support to the lateral elbow ligaments and is a key restraint against posterolateral rotatory instability.[29,30] It originates from the lateral epicondyle and courses posterior to the radial head before inserting on the supinator crest of the ulna. In this way, the LUCL prevents the ulna from rotating about its long axis away from the trochlea.[29] On conventional MR imaging, the LUCL is incompletely visualized in up to 23% of healthy volunteers.[29] Although the RCL also originates from the lateral epicondyle, this fan-shaped ligament runs longitudinally and blends distally with the annular ligament.

PATHOLOGY

The most common indication for MR arthrography of the elbow is medial joint pain, especially if occurring during overhand throwing. It is important to carefully assess all supporting structures, which should be easily visualized due to capsular distention by intra-articular contrast. Additionally, extra-articular etiologies for elbow pain should be evaluated as with any nonarthrographic study.

Ulnar Collateral Ligament Tear

Because the anterior bundle of the UCL is the most important stabilizer against valgus stress, it is no surprise that this ligament is most frequently injured in pitchers as a result of the high stresses placed on the joint during the late-cocking phase of throwing.[5,26,28,29] The UCL should be easily visualized on MR arthrography and is normally homogeneously hypointense along its superficial aspect proximally. The deep margin can be more heterogeneous in signal, which should not be confused with injury.[5,29]

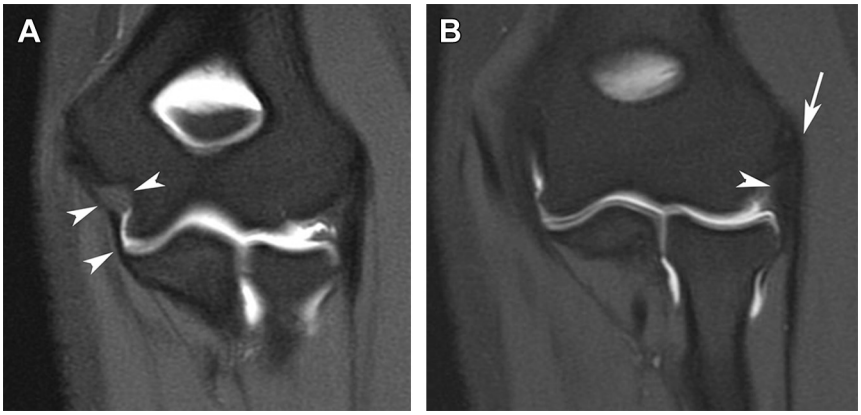

Fig. 11. Normal MR imaging arthrogram of the elbow in a 17 year-old girl with elbow pain. (*A*) Coronal image shows the normal fan-shaped configuration of the anterior bundle of the UCL (*arrowheads*), with normally increased signal intensity in the proximal ligament. (*B*) Coronal image show the normal RCL proper (*arrowhead*) deep to the intact common extensor tendon origin (*arrow*). MR arthrography adds value over conventional MR when there is the suspicion of partial-thickness tearing of the collateral ligaments in high-level athletes.

When the heterogeneity of the proximal UCL extends to involve the superficial aspect of the ligament, a partial-thickness tear should be suspected. Partial tears also can appear as a focal tear in the proximal UCL with its apex directed toward the superficial surface (Fig. 12).[5,26] Visualization of these partial tears is improved with arthrography, as contrast can be seen filling the tear and extending into the ligament (Fig. 13). These tears are of uncertain clinical significance, and athletes often continue to throw without surgical repair.[5,29]

The characteristic appearance of a partial tear of the distal UCL is referred to as the "T sign," due to contrast entering the defect and extending a short distance distally between the UCL and the proximal ulna (see Fig. 12). The anterior bundle normally inserts approximately 3 mm distal to the proximal margin of the sublime tubercle, so if there is contrast extending more than 3 mm distally, a partial tear should be suspected.[5,31] Whether or not these tears require surgical repair largely depends on the percentage of ligament involved and the degree to which contrast extends distal to the sublime tubercle. Schwartz and colleagues[32] demonstrated 86% sensitivity/100% specificity for detection of partial-thickness tears on arthrography.

Traumatic injury to the UCL also can be assessed with MR arthrography, although the abnormalities associated with acute trauma follow a less-reproducible pattern than those secondary to recurrent valgus stresses.[5] In cases of acute trauma, there are frequently associated injuries to the surrounding structures, including capsular disruption, fractures of the coronoid process of the ulna, articular cartilage delamination, and contusion.[5] The best indicator of traumatic disruption of the UCL is contrast extending medial to the joint line; the location of tear (ie, proximal or distal) is less important in the setting of trauma and these tears infrequently require reconstruction.

ULNAR COLLATERAL LIGAMENT RECONSTRUCTION

Reconstruction of the UCL is commonly performed in patients with medial elbow instability secondary to complete tears. In high-performing athletes, the tendency to return to a normal level of activity soon after surgery can lead to postoperative pathology.[33] In certain cases, evaluation with MR arthrography can be useful to evaluate the reconstruction as well as the adjacent elbow stabilizers. Due to the variable appearance of the reconstructed UCL in terms of thickness and signal characteristics, the best indicator of pathology is opacification of the fibers of the graft by intra-articular contrast (Fig. 14).[33] The reconstructed ligament is expected to be thickened and heterogeneous compared with the native ligament, and is anchored into the sublime tubercle more distal than the native ligament, allowing a small amount of contrast to extend into the recess normally. However, extravasation of medial joint fluid into the reconstructed ligament would be considered a tear.

Radial Collateral Ligament Complex

The radial collateral ligament complex is composed of the radial collateral ligament (RCL) proper, the lateral ulnar collateral ligament (LUCL), and the annular ligament.[34] The LUCL is

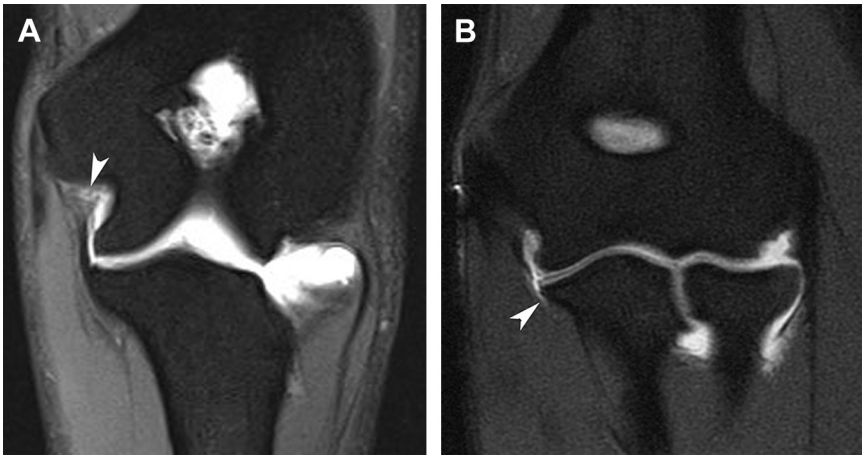

Fig. 12. Partial-thickness tear of the UCL. (*A*) Injected contrast extends into the deep proximal fibers (*arrowhead*) of the anterior band of the UCL in a 44-year-old who previously worked as a stuntman. (*B*) A 17-year-old baseball player producing the "T sign." Coronal MR arthrogram shows contrast dissecting proximally and distally along the undersurface of the UCL producing the "T sign" of a partial UCL tear (*white arrowhead*).

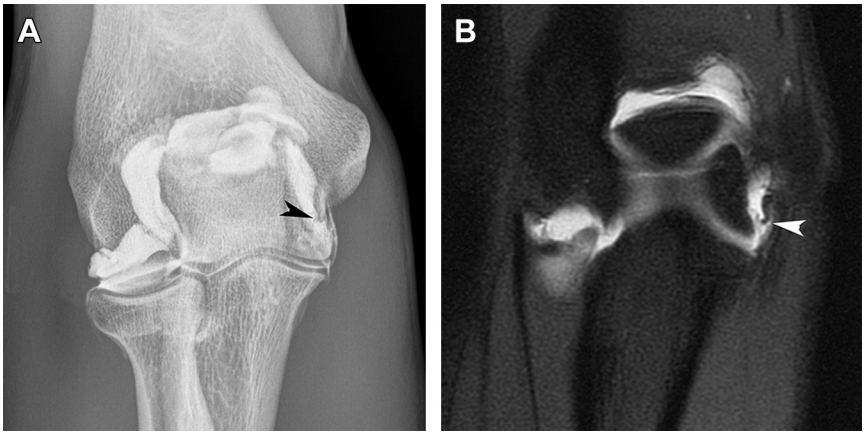

Fig. 13. Partial-thickness tear of the UCL. Fluoroscopic (*A*) and coronal MR arthrogram (*B*) both demonstrating contrast extending past the expected location of the UCL (*black arrowhead*). The MR arthrogram shows the partial tear with retraction of some of the torn fibers (*white arrowhead*).

the most frequently injured lateral ligament in the setting of traumatic subluxation or dislocation of the elbow.[5] The incidence of traumatic elbow dislocation is 5 to 6 per 100,000, surpassed only by dislocations of the shoulder.[29] The course of the LUCL along the inferior aspect of the proximal radius predisposes it to damage from translational forces. The normal LUCL should be taut and homogeneously low signal on MR arthrography; the presence of focal ligamentous thickening or laxity should raise suspicion for a tear. Complete tears can be seen as focal disruption with extravasation of contrast through the defect in the LUCL.[5] The RCL is located anterior to the LUCL and is also susceptible to injury in the setting of trauma (**Fig. 15**).[5] Detection of any abnormality involving the RCL or LUCL should prompt close scrutiny of the remaining lateral ligament. Posterolateral elbow instability can occur in the setting of chronic recurrent injury to the LUCL, as the ability of the ligament to resist rotational forces is diminished over time.

Laxity of the LUCL near its ulnar insertion allows rotation and possible subluxation of the ulnohumeral joint with eventual secondary dislocation of the radiohumeral joint.[5] Importantly, the annular ligament is not disrupted and the proximal radioulnar joint remains intact.

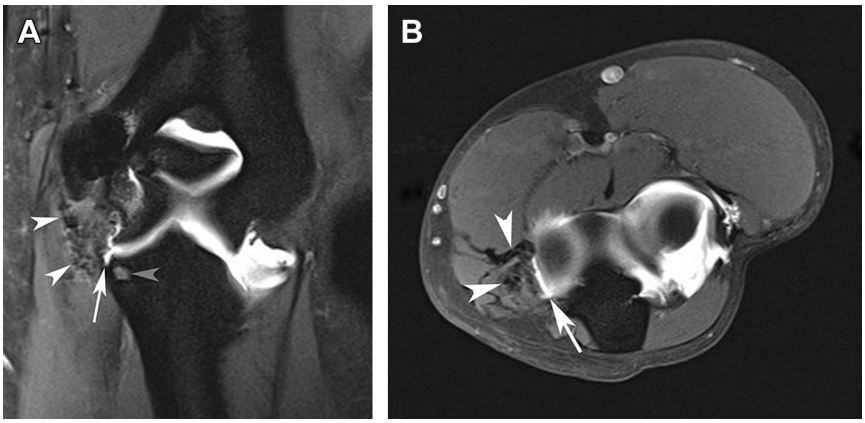

Fig. 14. Intact UCL reconstruction in a 27-year-old professional baseball pitcher. Coronal (*A*) and axial (*B*) images from MR arthrogram shows the normal postoperative appearance of an intact UCL ligament repair. The reconstructed ligament is expected to be thickened and heterogeneous (*white arrowheads*) compared with the native ligament, and is anchored into the sublime tubercle (*gray arrowhead*) more distal than the native ligament, allowing a small amount of contrast (*arrow*) to extend into the recess. (*B*) Axial image shows no extravasation of medial joint fluid (*arrow*) into the reconstructed ligament (*arrowheads*).

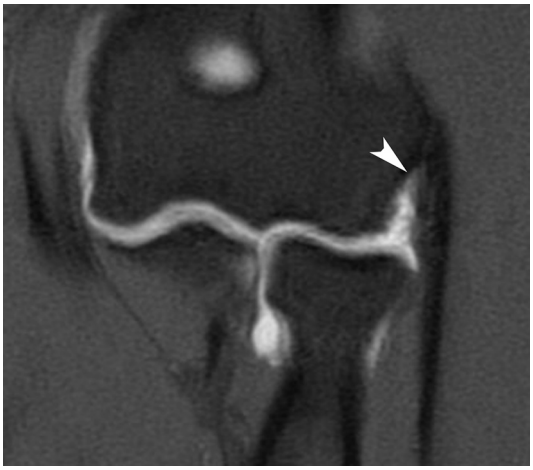

Fig. 15. High-grade tearing of the RCL in a 17-year-old boy after elbow dislocation 1 year prior. Coronal MR arthrogram shows high-grade tearing of the deep fibers of the proximal RCL (*arrowhead*), with intact overlying common extensor tendon origin. Patient also had healed coronoid process fracture (not shown).

Olecranon Stress Fracture

Osseous stress reaction, contusion, and fracture also may be detected on the fluid-sensitive sequences of elbow MR arthrography. Olecranon stress fractures in throwing athletes are caused by shear forces in the posterior compartment and chronic impingement.[1] Repetitive valgus elbow stress and rapid elbow extension during the late stages of throwing may result in olecranon microtrauma. These repetitive excessive forces may lead to olecranon stress fracture, with propagation from a structural weak point in the trochlear groove.[35] MR imaging is reserved for cases in which radiographs are inconclusive: injected contrast may extend into portions of incomplete fractures (**Fig. 16**) and associated bone marrow edema will be evident on fluid-sensitive sequences. Initial treatment of olecranon stress fractures is conservative and consists of rest and splinting. Screw fixation may be preferable so as to achieve early union in elite athletes and hasten return to play.[36,37]

Osteochondral Injuries and Osteochondritis Dissecans

Instability of the elbow predisposes to osteochondral and articular cartilage injury; these lesions are optimally evaluated with MR arthrography, as this carries greater sensitivity than routine MR imaging or CT arthrography.[5] Arthrographic evaluation of osteochondral injury is crucial for determining the stability of these lesions, which will determine if surgical intervention is required. Along the same disease spectrum, the presence of intra-articular bodies can be much better demonstrated with MR arthrography than with conventional imaging, as the insinuation of contrast between the fragment and adjacent bone greatly improves contrast resolution.

Osteochondritis dissecans (OCD) of the elbow is a specific manifestation of osteochondral injury seen classically in adolescent or young adult athletes, especially baseball pitchers. The characteristic distribution involves the radiocapitellar joint

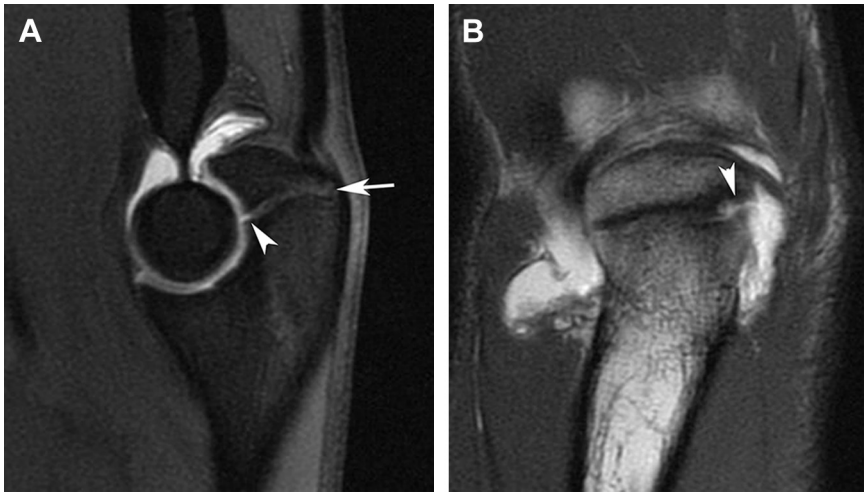

Fig. 16. Olecranon apophyseal stress fracture in a 17-year-old baseball player who also sustained partial-thickness tear of the UCL. (*A*, *B*) Sagittal T1-weighted fat-suppressed (*A*) and coronal T1-weighted (*B*) images show medial-sided stress fracture through the olecranon physis (*arrow*), with contrast extending into the medial and deep portions (*arrowheads*) of the physis.

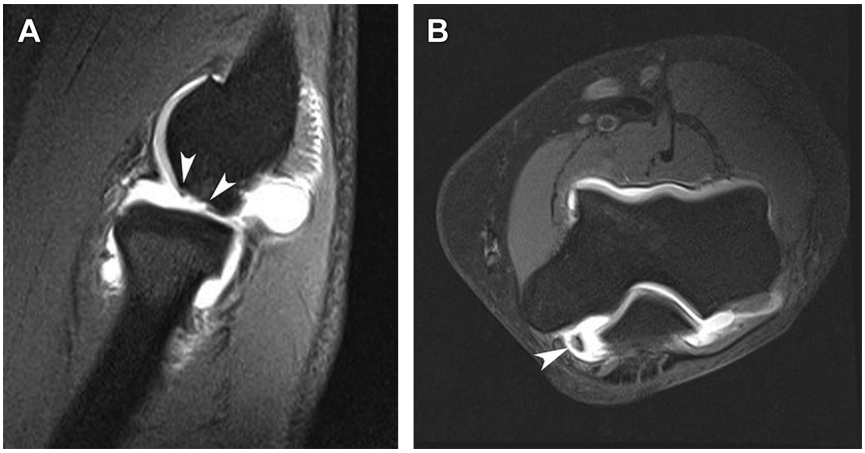

Fig. 17. OCD of the elbow. (*A*) Sagittal MR arthrographic images in a 14-year-old female athlete show a focal osteochondral defect along the articular surface of the capitellum (*white arrowheads*). (*B*) The presence of an intra-articular body (*white arrowhead*) in the olecranon recess on axial image demonstrates the end result of osteochondral instability with fragmentation.

most frequently due to repetitive valgus impaction injury of the radial head and developing ossification center of the capitellum during the late-cocking phase of pitching.[38] The pathogenesis of OCD is believed to be secondary to compromised vascular supply to the capitellum, resulting in osteochondral fragmentation and eventually, instability.[26,38] Arthrography plays a key role in determining the treatment pathway for these patients. Osteochondral injuries are visualized as irregularities along the articular surface, which fill in with intra-articular contrast.[5,38] Osteochondral instability is demonstrated by the insinuation of contrast between the fragment and underlying bone; these patients invariably require surgical repair with either pinning or excision of the osteochondral fragment. Intra-articular bodies may be present in advanced cases, and their detection is greatly improved with MR arthrography over conventional MR imaging, especially when the bodies are incompletely ossified (**Fig. 17**).[5,28,39]

SUMMARY

In conclusion, MR arthrography of the wrist and elbow is useful for detecting a variety of intra-articular pathologies, and has proven to be more sensitive and specific than conventional MR imaging. MR dictations should address whether intrinsic ligament tears of the wrist are partial-thickness or full-thickness, and involve the dorsal, membranous, and/or volar components of the ligaments. With regard to the elbow soft tissue pathology, partial-thickness tears of the anterior band of the UCL in overhead-throwing athletes are well evaluated with MR arthrography. The "T sign" should be sought by the radiologist in cases of partial tearing at the attachment of ligament onto the sublime tubercle. Repetitive valgus elbow stress and rapid elbow extension during the late stages of throwing may result in olecranon stress fracture, with propagation from a structural weak point in the trochlear groove. And finally, MR arthrography is helpful in staging OCD of the capitellum, caused by repetitive valgus impaction injury in adolescent or young adult baseball pitchers.

REFERENCES

1. Bancroft LW. Wrist injuries: a comparison between high- and low-impact sports. Radiol Clin North Am 2013;51(2):299–311.
2. Watanabe A, Souza F, Vezeridis PS, et al. Ulnar-sided wrist pain. II. Clinical imaging and treatment. Skeletal Radiol 2010;39(9):837–57.
3. Choudur HN, Ellins ML. Ultrasound-guided gadolinium joint injections for magnetic resonance arthrography. J Clin Ultrasound 2011;39(1):6–11.
4. Medverd JR, Pugsley JM, Harley JD, et al. Lateral approach for radiocarpal wrist arthrography. AJR Am J Roentgenol 2011;196(1):W58–60.
5. Delport AG, Zoga AC. MR and CT arthrography of the elbow. Semin Musculoskelet Radiol 2012;16(1):15–26.
6. DeFilippo M, Pogliacomi F, Bertellini A, et al. MDCT arthrography of the wrist: diagnostic accuracy and indications. Eur J Radiol 2010;74:221–5.
7. Daley EL, Bajaj S, Bisson LJ, et al. Improving injection accuracy of the elbow, knee, and shoulder: does injection site and imaging make a difference? A systematic review. Am J Sports Med 2011;39(3):656–62.

8. Saupe N, Zanetti M, Pfirrmann CW, et al. Pain and other side effects after MR arthrography: prospective evaluation in 1085 patients. Radiology 2009; 250(3):830–8.
9. Squires JH, England E, Mehta K, et al. The role of imaging in diagnosing diseases of the distal radioulnar joint, triangular fibrocartilage complex, and distal ulna. AJR Am J Roentgenol 2014;203(1): 146–53.
10. Chhabra A, Soldatos T, Thawait GK, et al. Current perspectives on the advantages of 3-T MR imaging of the wrist. Radiographics 2012;32(3):879–96.
11. Donati OF, Nordmeyer-Massner J, Nanz D, et al. Direct MR arthrography of cadaveric wrists: comparison between MR imaging at 3.0T and 7.0T and gross pathologic inspection. J Magn Reson Imaging 2011;34(6):1333–40.
12. Scheck RK, Kubitzek C, Hierner R, et al. The scapholunate interosseous ligament in MR arthrography of the wrist: correlation with non-enhanced MRI and wrist arthroscopy. Skeletal Radiol 1997; 26:263–71.
13. Ringler MD. MRI of wrist ligaments. J Hand Surg Am 2013;38(10):2034–46.
14. Cerny M, Marlois R, Theumann N, et al. 3-T direct MR arthrography of the wrist: value of finger trap distraction to assess intrinsic ligament and triangular fibrocartilage complex tears. Eur J Radiol 2013; 82(10):e582–9.
15. Kirchgesner T, Pesquer L, Larbi A, et al. Axial traction in magnetic resonance arthrography of the wrist: How to do? Diagn Interv Imaging 2014 [pii:S2211-5684(14) 00194–6]. [Epub ahead of print].
16. Garcia-Elias M, Geissler WB. Carpal instability. In: Green DP, Hotchkiss RN, Pederson WC, et al, editors. Green's operative hand surgery. Philadelphia: Elsevier Churchill Livingstone; 2005. p. 535–604.
17. Cerezal L, de Dios Berná-Mestre J, Canga A, et al. MR and CT arthrography of the wrist. Semin Musculoskelet Radiol 2012;16(1):27–41.
18. Lee RK, Ng AW, Tong CS, et al. Intrinsic ligament and triangular fibrocartilage complex tears of the wrist: comparison of MDCT arthrography, conventional 3-T MRI, and MR arthrography. Skeletal Radiol 2013;42(9):1277–85.
19. Lee YH, Choi YR, Kim S, et al. Intrinsic ligament and triangular fibrocartilage complex (TFCC) tears of the wrist: comparison of isovolumetric 3D-THRIVE sequence MR arthrography and conventional MR image at 3 T. Magn Reson Imaging 2013;31(2): 221–6.
20. Moser T, Khoury V, Harris PG, et al. MDCT arthrography or MR arthrography for imaging the wrist joint? Semin Musculoskelet Radiol 2009;13(1):39–54.
21. Porteous R, Harish S, Parasu N. Imaging of ulnar-sided wrist pain. Can Assoc Radiol J 2012;63(1): 18–29.
22. Mak WH, Szabo RM, Myo GK. Assessment of volar radiocarpal ligaments: MR arthrographic and arthroscopic correlation. AJR Am J Roentgenol 2012; 198(2):423–7.
23. Taljanovic MS, Malan JJ, Sheppard JE. Normal anatomy of the extrinsic capsular wrist ligaments by 3-T MRI and high-resolution ultrasonography. Semin Musculoskelet Radiol 2012;16(2):104–14.
24. Muminagic S, Kapidzic T. Wrist instability after injury. Mater Sociomed 2012;24(2):121–4.
25. Magee T. Comparison of 3-T MRI and arthroscopy of intrinsic wrist ligament and TFCC tears. AJR Am J Roentgenol 2009;192(1):80–5.
26. Dewan AK, Chhabra AB, Khanna AJ, et al. MRI of the elbow: techniques and spectrum of disease: AAOS exhibit selection. J Bone Joint Surg Am 2013;95(14):e99, 1–13.
27. Lohman M, Borrero C, Casagranda B, et al. The posterior transtriceps approach for elbow arthrography: a forgotten technique? Skeletal Radiol 2009;38(5): 513–6.
28. Lomasney LM, Choi H, Jayanthi N. Magnetic resonance arthrography of the upper extremity. Radiol Clin North Am 2013;51(2):227–37.
29. Schaeffeler C, Waldt S, Woertler K. Traumatic instability of the elbow - anatomy, pathomechanisms and presentation on imaging. Eur Radiol 2013;23(9): 2582–93.
30. Sanal HT, Chen L, Haghighi P, et al. Annular ligament of the elbow: MR arthrography appearance with anatomic and histologic correlation. AJR Am J Roentgenol 2009;193(2):W122–6.
31. Anderson MW, Alford BA. Overhead throwing injuries of the shoulder and elbow. Radiol Clin North Am 2010;48(6):1137–54.
32. Schwartz ML, Al-Zahrani S, Morwessel RM, et al. Ulnar collateral ligament injury in the throwing athlete: Evaluation with saline-enhanced MR arthrography. Radiology 1995;197:297–9.
33. Wear SA, Thornton DD, Schwartz ML, et al. MRI of the reconstructed ulnar collateral ligament. AJR Am J Roentgenol 2011;197(5):1198–204.
34. Jacobson JA, Chiavaras MM, Lawton JM, et al. Radial collateral ligament of the elbow: sonographic characterization with cadaveric dissection correlation and magnetic resonance arthrography. J Ultrasound Med 2014;33(6):1041–8.
35. Blake JJ, Block JJ, Hannah GA, et al. Unusual stress fracture in an adolescent baseball pitcher affecting the trochlear groove of the olecranon. Pediatr Radiol 2008;38:788–90.
36. Sheehan SE, Dyer GS, Sodisckson AD, et al. Traumatic elbow injuries: what the orthopedic surgeon wants to know. RadioGraphics 2013;33:869–88.
37. Rauck RC, Lamont LE, Doyle SM. Pediatric upper extremity stress injuries. Curr Opin Pediatr 2013; 25(1):40–5.

38. Ruchelsman DE, Hall MP, Youm T. Osteochondritis dissecans of the capitellum: current concepts. J Am Acad Orthop Surg 2010;18(9):557–67.

39. Theodoropoulos JS, Dwyer T, Wolin PM. Correlation of preoperative MRI and MRA with arthroscopically proven articular cartilage lesions of the elbow. Clin J Sport Med 2012;22(5):403–7.